





ORIGINAL ARTICLE

Endolift laser an effective treatment modality for forehead wrinkles and frown line

Mohammad Ali Nilforoushzadeh MD^{1,2}  | Tannaz Fakhim MD^{1,2}  | Maryam Heidari-Kharaji PhD^{1,2,3}  | Elham Torkamaniha PhD^{1,2,4}  | Maryam Nouri MD¹ | Masoumeh Roohaninasab MD⁵ | Elham Behrangi MD⁵ | Amirreza Hanifnia MD² | Azadeh Goodarzi MD⁵

¹Skin and Stem Cell Research Center, Tehran University of Medical Sciences, Tehran, Iran

²Jordan Dermatology and Hair Transplantation Center, Tehran, Iran

³Institut National de la Recherche Scientifique (INRS), Centre Armand-Frappier Santé Biotechnologie (CAFSB), Laval, Quebec, Canada

⁴Department of Microbial Biotechnology, Islamic Azad University, Kish Branch, Tehran, Iran

⁵Department of Dermatology, Rasool Akram Medical Complex, Iran University of Medical Sciences, Tehran, Iran

Correspondence

Azadeh Goodarzi, Department of Dermatology, Rasool Akram Medical Complex, Iran University of Medical Sciences, Tehran, Iran.
Email: Goodarzi.az@gmail.com

Abstract

Background: The search of beauty and youth has received a lot of attention which is proved by increasing cosmetic techniques. The people prefer non-surgical and invasive method for reduction and wrinkles treatment.

Methods: In this study, we used Endolift laser for forehead wrinkles and frown line treatment to evaluate the clinical safety and effectiveness of this technique for reduction of forehead wrinkles and frown line. A total of 9 patients with forehead wrinkles and frown line were included in the current study. The results were investigated using biometric evaluation. Also, assessment was performed clinically and photographically, and physician's assessment and patient satisfaction responses were recorded.

Results: According to the biometric results, the skin thickness and elasticity significantly increase after Endolift laser treatment. According to the physician's assessment, 90% of patients displayed very much improvement after Endolift laser treatment, and according to the patient assessment, 91% of patients reported positive satisfaction response.

Conclusion: Treatment with Endolift laser is safe and an effective method for decrease of forehead wrinkles and frown line treatment. It offers as a non-invasive alternative technique in compared to other invasive procedures for forehead wrinkles and frown line treatment.

KEYWORDS

aging, endolift laser, forehead wrinkles, frown line, treatment

1 | INTRODUCTION

The upper part of the face is a dynamic and complex part of the face, that expresses emotions and feelings.¹ With age, the forehead young dynamic lines and glabella become permanent wrinkles, that stay at rest on the face. These wrinkles can cause the look of tiredness and undesirable expressions of facial like anger, that can affect mental health, self-confidence, and self-worth. Wrinkles on the

forehead are because of a combination of environmental and genetic factors.² Young appearance, soft and symmetry, smooth texture of skin are the key features of beautiful and attractive faces.^{3,4} Aging affected these factors, that is set for every human being. The wrinkles of facial are the most apparent characteristic of aging.⁵ Therefore, many therapeutic methods in cosmetology science target facial wrinkles.^{2,6} The first place on the face that shows wrinkles is the forehead and after that glabella. In both sexes, forehead

wrinkles increase with age specially in men.⁷ Simultaneously with the development of wrinkles on the forehead, a frown line is also appeared. Glabellar frown line in the people is caused by excessive contractions of the facial muscles. Also, musculature hyperactivity, resulting in loss of elasticity, is appeared as a result of the subcutaneous muscles excessive stimulation in the forehead, like the muscles of the procerus and corrugator supercilii.^{8,9} Also, frequent muscle cell contractions can enhance the fibrocytes metabolic activity and lead to the hypodermal connective tissue remodeling, that lead to a frown line.⁸ Age-related skin collagen changes may also be related to the form of wrinkles and frown lines.⁸ Additionally, in the area of the forehead wrinkles, the dermis becomes thinner in compare to the other parts of the forehead dermis and this decrease progressively advance by age.^{10,11} Present routes for cosmetic cure of facial wrinkle and frown line include botulinum toxin type A (BTX) injection, surgery, and implants. Surgical options contain endoscopic brow surgery, coronal brow lift, 4.5, chemical peels, and dermabrasion. Substances implantation like silicone, collagen, 8 polytetrafluoroethylene 10, or autologous fats, 9 also has been used to rejuvenate and remove forehead wrinkles and frown lines. Most patients with the severe forehead wrinkles and frown lines do not agree with surgical procedures or would simply like a less invasive treatment to fit their busy lifestyles. Recently, laser therapy has been used to treat the forehead wrinkle and glabellar frown line. The ablative lasers, like Erbium Laser, eliminate the external skin layer. It, at the same time, warmth the deeper layers of the skin to increase growth of new collagen fibers. The most of the patients looking for non-ablative laser therapy. Endolift laser as non-ablative laser can improve facial wrinkles and glabellar frown line as well as develop the texture and tone of the skin. Endolift laser stimulates collagen growth, increases the thickness of the dermis, and makes tighter underlying skin with no skin wounding. In this study, the

effect of Endolift laser was evaluated on the forehead wrinkle and glabellar frown line treatment.

2 | PATIENTS AND METHODS

2.1 | Subjects

A total of 9 healthy female and male suffering forehead wrinkle and frown line aging from 35 to 65 years old were participate in this study. Exclusion criteria contain bleeding diathesis, pregnancy, lactation, and previous treatment such as botulinum toxin treatments or injection of dermal filler in the forehead within 6 months. In this study, all included patients make signed the form of informed consent. The form comprised details concerning the procedure, involvement in this experiment, and the possible usage of their medical data.

2.2 | Procedure

Each subject with deep frown line and forehead wrinkles was treated with Endolift™ (LASEMAR1500TM machine, Eufoton s.r.l.) with the power: 75 watt, energy: 600–800 J, pulse: 25, and fiber: 200–300 micron. All subjects received injectable or local anesthesia with lidocaine. The size of fiber was depending on the depth of the wrinkles and the thickness of the skin. The fiber was moved under the wrinkle; for horizontal wrinkles, the fiber was moved horizontally; and for vertical wrinkles, it was moved vertically. The movement of the fiber was reciprocating in the intervention area. The time of process varies from person to person and depends on the depth and number of the wrinkles. This technique does not need recovery time. The follow-up was done for 6 months after treatment.

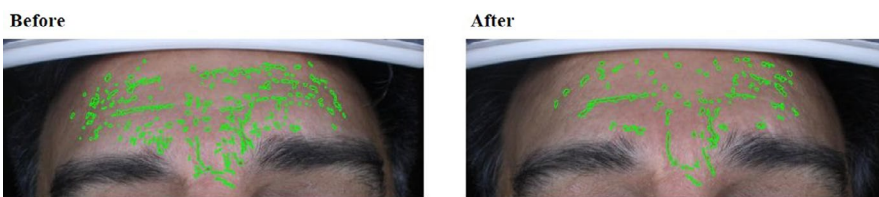


Image	Volume	Area	Depth	%-Area
1	397,629px ³	39,205px ²	10px	3.292%
2	255,572px ³	23,654px ²	10px	1.986%

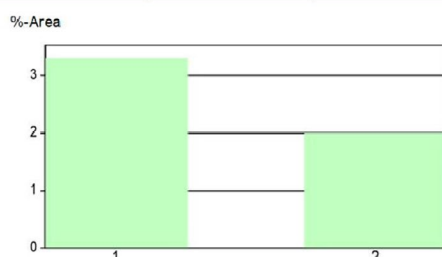


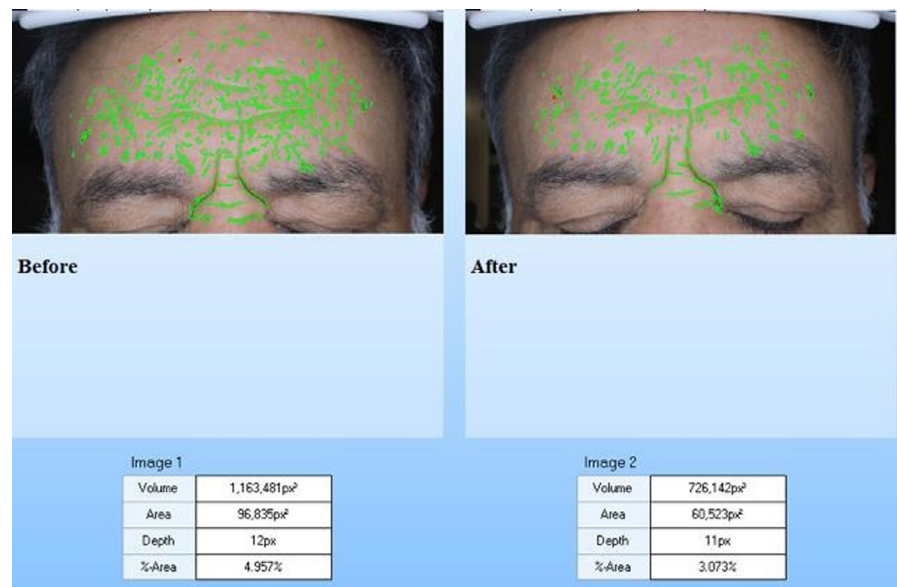
FIGURE 1 Visioface wrinkle analysis showed significantly improvement in the wrinkle and frown line

2.3 | Measurement

2.3.1 | Biometric evaluation

For each subject, Visioface (D1000 ck) photographs were gotten with a camera before and after treatment. Biometric features of each subject were measured by Visioface, (multi-probe adapter) to analysis the changes in depth and volume and area of the wrinkles and Cutometer (L parameter), (Courage + Khazaka Electronics) to calculate the elasticity of the skin with preparing R2, R5, R7 parameters (R2: Visco-elasticity in % (resistance to the mechanical force vs. ability of recovery); eR5: Net elasticity in %: $Ur/Ue =$ elastic part of the suction phase vs. immediate recovery during relaxation phase.; fR 7:

FIGURE 2 Results display decrease in volume, area, and depth of forehead wrinkle and frown line after treatment



Ur/Uf proportion of the immediate recovery compared to the amplitude after suction in %). Also, skin ultrasound imaging system (TPM) was used to evaluate the thickness of the skin layers, before and after treatment.

2.3.2 | The patients' opinions

The patients' pretreatment and post-treatment photography were taken. The patient's opinions about outcomes were documented based on a scale from 0 to 4:

poor results (0–1), fair results (2), good results (3), and excellent results (4).

TABLE 1 Comparing biometric characteristics of the skin before and 6 months after treatment

	Measured values		Percent change	p value
	Before	After		
Visioface				
Wrinkle				
Depth	0.60 ± 0.17	0.42 ± 0.16	30.66 ± 5.46	<0.05
Area	0.45 ± 0.17	0.33 ± 0.19	26.65 ± 9.73	<0.05
Skin ultrasonography				
Skin density	16.00 ± 5.12	22.13 ± 10.56	38.31 ± 10.35	<0.05
Skin thickness	975.15 ± 204.62	1299.15 ± 206.17	33.72 ± 16.23	<0.05
Epidermis density	90.14 ± 23.16	118.19 ± 28.12	33.1 ± 13.41	<0.05
Epidermis thickness	74.40 ± 18.17	97 ± 22.15	31.23 ± 13.32	<0.05
Dermis density	8.60 ± 3.79	12.23 ± 8.71	50.42 ± 12.39	<0.05
Dermis thickness	884.71 ± 141.17	1190.34 ± 156.12	34.6 ± 10.50	<0.05
Density ^a				
R2	0.60 ± 0.21	0.83 ± 0.03	38.3 ± 8.18	<0.05
R5	0.51 ± 0.11	0.74 ± 0.11	45.03 ± 13.18	<0.05
R7	0.31 ± 0.05	0.45 ± 0.03	45.41 ± 10.26	<0.05

^aDensity of the skin measured by Cutometer.

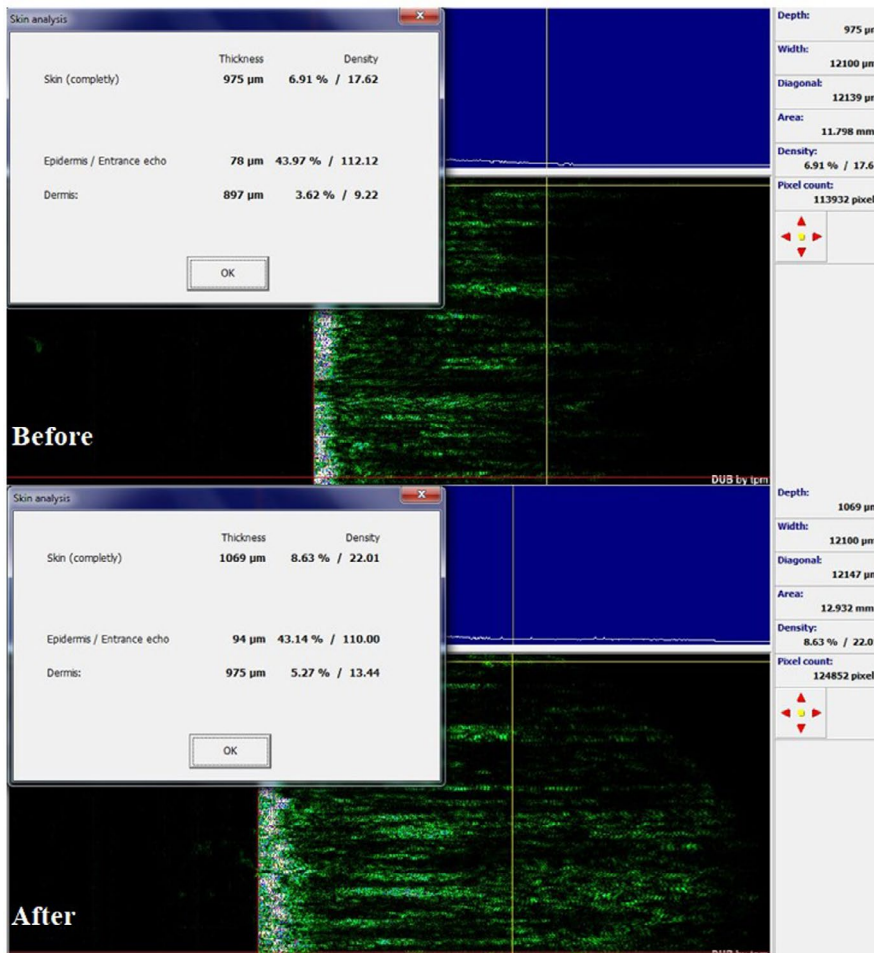


FIGURE 3 Skin analysis with ultrasonography Before and After treatment. Increase in skin density, epidermal density and dermal density after 6 months was seen

TABLE 2 Results of the patient assessment 6 months after treatment

Improvement grad	Subject satisfaction (%) (Mean ± SD)	p value
Poor	0%	<i>p</i> < 0.05
Fair	2.1%	
Good	6.3%	
Excellent	91.6%	

2.3.3 | Physician assessment

Physicians (blind) individually evaluated wrinkles in accordance with a scale classified 1 to 4, with 1 indicating no change, 2 indicating improved, 3 indicating much improved, and 4 indicating very much improved.

2.4 | Data analysis

The results were collected and arranged for statistical analysis. The data were evaluated by paired sample *t*-test with SPSS program version 22.0. The *p* value was calculated to identify the significance of the data.

3 | RESULTS

3.1 | Biometric evaluation results

The Visioface outcomes showed that the treatment can significantly decline the depth and area of skin wrinkle, and the percentages of change for depth and area were 30.66 ± 5.46 and 26.65 ± 9.73 , respectively (*p* < 0.05; Figures 1 and 2, Table 1). Furthermore, the skin ultrasonography data presented denser in the dermis and epidermis (Figure 3; Table 1). As displayed in Table 1, a significant increase was observed in the epidermis and dermis density and thickness and the percentages of change in epidermis thickness and density were 31.23 ± 13.32 and 33.1 ± 13.41 and in dermis thickness and density were 50.42 ± 12.39 and 34.6 ± 10.50 (*p* < 0.05). Also, the Cutometer results showed that the treatment caused a higher skin elasticity (*p* < 0.05) (Table 1).

3.2 | The patient's and physician's assessment results

The percentage of patient satisfaction is shown in Table 2. The results show that about 91% of patients reported excellent improvement after treatment. Except for mild erythema and edema,

Level	Physician satisfaction (%) (Mean \pm SD)			
	Physician 1	Physician 2	Physician 3	<i>p</i> value
Very much improved (4)	93 \pm 3.3	90 \pm 3.2	89 \pm 4.1	<i>p</i> < 0.05
Much improved (3)	6 \pm 1.3	8 \pm 1.1	8 \pm 2.3	
Improved (2)	1 \pm 1.1	2 \pm 2.5	3 \pm 1.5	
No change (1)	0	0	0	

TABLE 3 Percentage of physician's satisfaction after 6 months

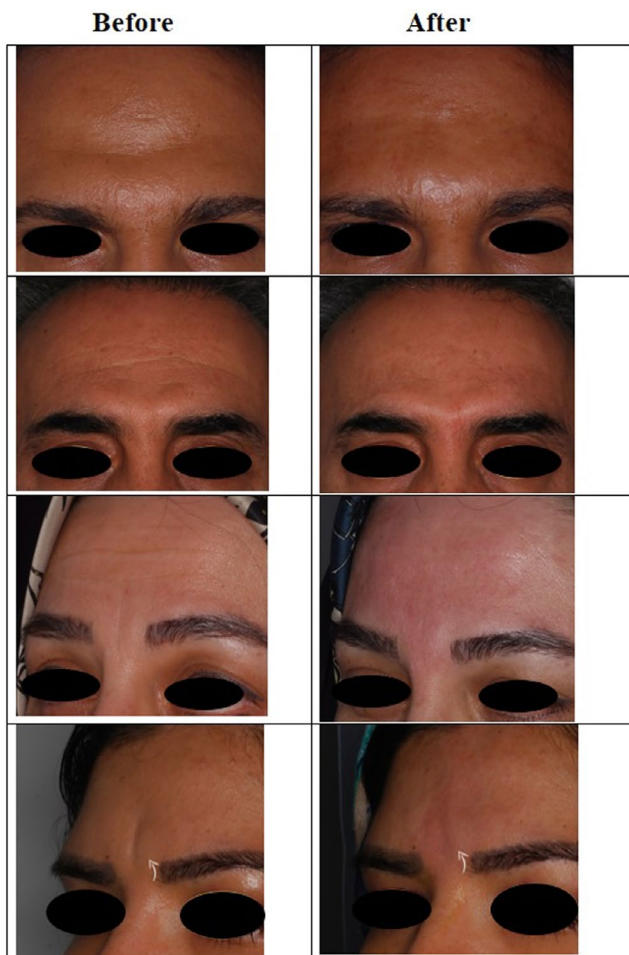

FIGURE 4 Study subjects before and 6 months after the Endolift treatment

the patients reported no side effects for the combination therapy. Similarly, the physicians informed about 90% of patients showed very much improved after Endolift laser treatment (Table 3). Also, the photographs taken before and after treatment to assess the final changes of the patients (Figure 4).

4 | DISCUSSION

In the current study, we used Endolift laser for treatment of deep wrinkles on the upper face and frown line and the results showed

that Endolift laser can significantly decrease the depth and area of skin wrinkle and increase the epidermis and dermis density and thickness and elasticity of the skin. Numerous factors contribute in the development of forehead wrinkles, like environmental, heredity, and biochemical factor, wherein skin aging and repetitive muscle contraction are the two main elements.¹² The mimetic muscle repetitive contraction causes facial skin wrinkled, and the aging of the skin can result in loss of matrix materials and dermal collagen, that cause the skin lose its elasticity and thickness. So, the procedure which increase in the elasticity and thickness of the skin can be an effective method for forehead lines treatment. Patients with deep forehead wrinkles and frown lines often seek for treatment since the appearance of annoyed or angry. Also, they usually ask for a non-invasive method. Currently, different methods use for treatment. More of recent treatment options like surgery, botulinumtoxinA (BTXA) injection, or implants are invasive. In the research of Wang et al.,¹³ the effect of autologous fibroblast and keratin injection was evaluated on treatment of static forehead rhytides. In another study, the dermal subcision technique was used for the forehead wrinkles treatment.¹⁴ However, the current methods have many side effects. So far, many of the surgical techniques for rejuvenation of forehead and lifts frequently leave potentially and long detectable scars, as well as possible risks to the supratrochlear and supraorbital nerves with an extremely high hair line.¹⁵ BTXA treatment for wrinkles of forehead, as an easy treatment technique, has some weaknesses.¹⁴ The treatment area for BTXA in the forehead is restricted to prevent eyebrow ptosis therefore.¹⁶ Also, repeated BTXA forehead treatment may cause a permanent muscle atrophy.¹⁴ Although rare, in some cases, after repeated injection resistance to BTXA is seen because of antibody formation.¹⁷ Also, brow ptosis is informed frequency after horizontal forehead lines BTXA treatment.¹⁸ Endolift laser as a non-invasive method is desirable for treatment of the skin disorder, and recently, it has been very popular.^{19,20} In this study, we used Endolift laser for treatment of deep wrinkles on the upper face and frown line. In comparison with the surgery, the Endolift laser treatment is well liked for its effective outcomes and slight invasiveness. Endolift laser is safe, and this technique has not any scars and does not alter the level of hairline. Also, this technique is safe for supraorbital and supratrochlear nerves and no need to recovery time. It is worth noting that in this study the safety and efficacy of Endolift laser were evaluated. Therefore, this method was not tested with any other technique for rejuvenation of forehead. In this study, authors selected the patients with never dermal filler injection in the

forehead and stop BOTOX injections six months before Endolift laser treatment. According to our results, Endolift laser can increase the thickness and density of dermis and epidermis. Also, the elasticity of the skin increase after Endolift laser therapy. The Endolift laser of the forehead wrinkles and frown line is a safe and effective method and can surely be a newly added option for forehead wrinkles and frown line treatment.

5 | CONCLUSION

In summary, Endolift laser is an effective healing route for the treatment of forehead wrinkles and frown lines, according to biometric evaluation and both physician and subject assessments, and Endolift laser can be a good alternative for other treatment because this technique is non-invasive and is well tolerated. Also, Endolift laser has not any scars. Furthermore, this technique is safe for supraorbital and supratrochlear nerves and no need to recovery time.

6 | LIMITATIONS

The lack of histology data is the limitation of the study.

ACKNOWLEDGEMENT

We admiringly acknowledge the colleagues and staffs in Skin and Stem Cell Research Center, Tehran University of Medical Sciences, Tehran, Iran, and Jordan Dermatology and Hair Transplantation Center, Tehran, Iran.

CONFLICT OF INTEREST

The authors declare no conflicts of interest.

AUTHOR CONTRIBUTIONS

N. MA and F. T, B. E, R. M, B. E, G. A and H. AM performed the research. N. MA designed the research study. H-K.M analyzed the data. T. E and N.M collected the data.


ETHICS STATEMENT

The patients have assigned their informed agreement for the photographs and details.

DATA AVAILABILITY STATEMENT

The data that support the findings of this study are available from the corresponding author upon reasonable request.

ORCID

Mohammad Ali Nilforoushzadeh  <https://orcid.org/0000-0001-6143-8039>

Tannaz Fakhim  <https://orcid.org/0000-0003-2206-6177>

Maryam Heidari-Kharaji  <https://orcid.org/0000-0001-6954-7942>

Elham Torkamaniha  <https://orcid.org/0000-0003-3116-3163>

REFERENCES

1. Dharmarajan T. Physiology of aging. *Geriatric Gastroenterology*; 2021:101-153.
2. Mohiuddin AK. Skin aging & modern age anti-aging strategies. *PharmaTutor*. 2019;7(8):22-70.
3. Fink B, Grammer K, Thornhill R. Human (Homo sapiens) facial attractiveness in relation to skin texture and color. *J Comp Psychol*. 2001;115(1):92.
4. Fink B, Neave N. The biology of facial beauty. *Int J Cosmet Sci*. 2005;27(6):317-325.
5. Kligman AM, Zheng P, Lavker RM. The anatomy and pathogenesis of wrinkles. *Br J Dermatol*. 1985;113(1):37-42.
6. Dulguerov N, D'Souza A. Update on treatment rationale and options for the ageing face. *Curr Opin Otolaryngol Head Neck Surg*. 2011;19(4):269-275.
7. Lueberding S, Krueger N, Kerscher M. Quantification of age-related facial wrinkles in men and women using a three-dimensional fringe projection method and validated assessment scales. *Dermatol Surg*. 2014;40(1):22-32.
8. Piérard GE, Lapière CM. The microanatomical basis of facial frown lines. *Arch Dermatol*. 1989;125(8):1090-1092.
9. Pribitkin EA, Greco TM, Goode RL, Keane WM. Patient selection in the treatment of glabellar wrinkles with botulinum toxin type A injection. *Arch Otolaryngol Head Neck Surg*. 1997;123(3):321-326.
10. Nemoto M, Uchinuma E, Yamashina S. Three-dimensional analysis of forehead wrinkles. *Aesthet Plast Surg*. 2002;26(1):10-16.
11. Tsukahara K. The relationship between wrinkle depth and dermal thickness in the forehead and lateral canthal region. *Arch Dermatol*. 2011;147(7):822-828.
12. Kang SH, Moon SH, Rho B-I, Youn SJ, Kim HS. Wedge-shaped polydioxanone threads in a folded configuration ("Solid fillers"): A treatment option for deep static wrinkles on the upper face. *J Cosmet Dermatol*. 2019;18(1):65-70.
13. Wang B, Yang J, Guan Y, Zhang J, Zhang Q. A new treatment for static forehead rhytides: Autologous fibroblast and keratin injection. *J Cosmet Dermatol*. 2021;20(10):3308-3314.
14. Elmelegy NG, Hegazy AM. Dermal subcision of Nemoto's ligaments as a long-lasting treatment for forehead and glabellar wrinkles. *Eur J Plast Surg*. 2019;42(2):125-134.
15. Harrison DH. Plastic and reconstructive surgery: approaches and techniques. *J Plast Reconstr Aesthet Surg*. 2015;68(12):1777.
16. De Maio M, Rzany B. *Botulinum Toxin in Aesthetic Medicine*. Springer Science & Business Media; 2007.
17. Torres S, Hamilton M, Sanches E, Starovatova P, Gubanova E, Reshetnikova T. Neutralizing antibodies to botulinum neurotoxin type A in aesthetic medicine: five case reports. *Clin Cosmet Investig Dermatol*. 2014;7:11.
18. Lorenc ZP, Smith S, Nestor M, Nelson D, Moradi A. Understanding the functional anatomy of the frontalis and glabellar complex for optimal aesthetic botulinum toxin type A therapy. *Aesthet Plast Surg*. 2013;37(5):975-983.
19. Nilforoushzadeh MA, Fakhim T, Heidari-Kharaji M, Hanifnia AR, Hejazi S, Torkamaniha E. Efficacy evaluation of Endolift-based subcision on acne scar treatment. *J Cosmet Dermatol*. 2021;20(8):2579-2582.
20. Roberto M. Endolift for the best face and body non-surgical lifting. *Plast Surg Case Stud*. 2020;5(1):1-2.

How to cite this article: Nilforoushzadeh MA, Fakhim T, Heidari-Kharaji M, et al. Endolift laser an effective treatment modality for forehead wrinkles and frown line. *J Cosmet Dermatol*. 2022;00:1-6. doi:[10.1111/jocd.14884](https://doi.org/10.1111/jocd.14884)