

EJAMeD

www.ejamed.com

The European Journal of
Aesthetic Medicine and Dermatology



Endolaser soft-lift: a new approach on body contouring. Perspective and suggestions

Luca Scrimali MD¹, Giuseppe Lomeo MD, Roberto Dell'Avanzato MD, Angelo Crippa MD

¹University of Catania, Plastic Surgery, Catania, Italy

ABSTRACT

Recently lifting and body remodeling techniques have gone through a great development, looking for less invasive and traumatic methods, due to the considerable number of people that have fear to undergo surgery. In this regard, very encouraging results have been obtained with the use of lasers, which seems to represent the future of cosmetic surgery in body contouring. What we would like to point out in this study is the effect of laser on skin tightening and retraction; This is possible for its photothermal action on subdermal tissues and allows similar outcomes compared to classic thread lift, with greater comfort for the patient, less pain and scars, less complications and shorter recovery time. We used a 1470 nm diode laser, which is a non-ablative laser that goes deep in the tissues due to its high affinity for fat and water.

KEYWORDS: laser, laserlift, endolift, skin tightening

Eur. J. Aesth. Medicine and Dermatology. 2013;3(3):86-90

INTRODUCTION

In the last years, patients request of lifting and body remodeling procedures, due to bad lifestyle's habits, have grown; an increasing number of new methods, less invasive and less traumatic have been proposed; despite the widespread distribution of cosmetic surgery, a considerable number of people have fear to undergo surgery. In this regard, very encouraging results have

been obtained with the use of laser, which seems to represent the future of the cosmetic surgery in body contouring.

What we would like to point out in this study is the effect of laser on skin tightening and retraction due to its photothermal action on the subdermal tissues, allowing to achieve similar outcomes compared to classic thread lift, with greater comfort for

CORRESPONDENCE

Luca Scrimali MD
University of Catania, Plastic Surgery Unit, Catania, Italy
luca.scrimali@gmail.com

DISCLOSURES

Author disclose any commercial associations or financial disclosures that might pose or create a conflict of interest with information presented in the manuscript.

the patient, less pain and scarring, minor risk of complications and a shorter recovery time.

We used a 1470 nm diode laser, which is a nonablative laser able to penetrate deeply in tissues due to its high affinity for fat and water.

MATERIALS AND METHODS

The laser we tested is a Diode laser for Endolift technique, emitting at 1470 nm (Eufoton Lasemar 1500, Via Flavia 23/1, 34148 Trieste, Italy). The light is delivered to the skin by an optic fiber of 100, 200, 300, 400, 600, 800 and 1000 nm. The laser is equipped with a fractional scanner which can be used both with 200 or 400 microns power cables.

To obtain several vectors of traction, the Endolift technique, can be performed with a cannula, inserted through a tab incision into the skin, reaching the junction between deep dermis and superficial layer of sub-

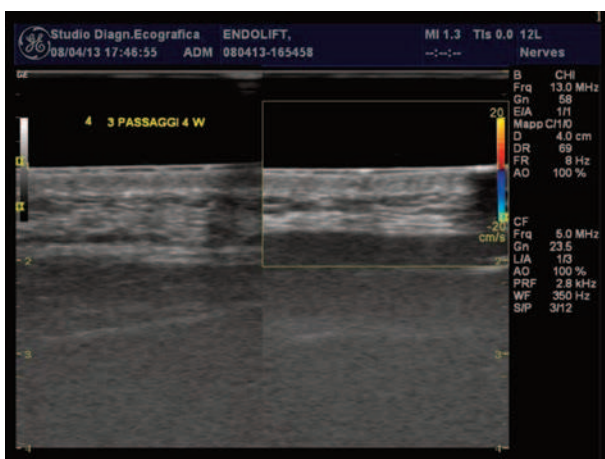
dermic fat.

We checked the right position of the cannula with ultrasonographic examination while performing the treatment; 3 weeks after, the same examination was performed to demonstrate the fibrosis obtained by laser and cannula.

The result in tightening few weeks after, continues for the next three months approximately, according to wound healing process, achieving better results month after month.

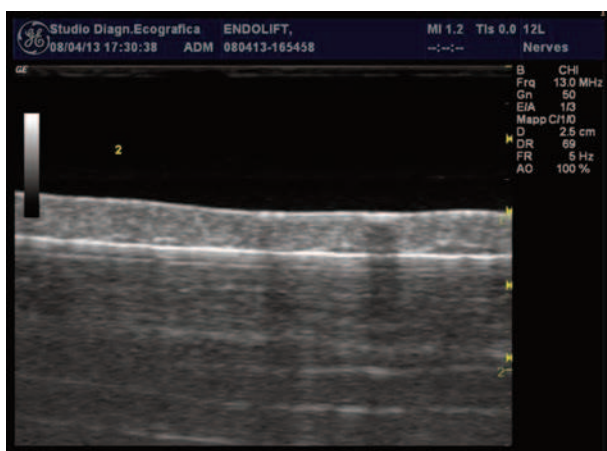
The cannula should go forward and backward 3 times each tunnel, emitting laser light while moving back. The number of tunnels depends on the treated area and could vary from a minimum of 3 to a maximum of 10. Thus tunnels must be oriented according to antigravitational lines to obtain the right traction.

Alternatively (but only in expert hands) this technique can be performed with a free fiber, especially in areas where the skin is very thin, like cheek and neck, or in small areas like the peri umbelical area or the medial aspect of thigh and knees.



At the end of the treatment, that must be repeated three times in a month, the patient will have a compressive dressing to keep in place 24h a day for the first 4 days post-op and only during the night for 4 more days.. The treatment can be performed in local anesthesia, there is no pain after treatment despite a burning sensation for at least 4-5 h, that can be controlled with oral painkiller. An antibiotic therapy is suggested in the next 3-5 days after treatment.

An aedema can occur in treated areas, for



about 5/6 days; it will resolve spontaneously, without any drugs; a mild massage could help resolving it more fast. Ecchymosis can occur in the treated areas, and it will resolve spontaneously within 7/10 days.

The follow up is at least 8 months, because this is the time the subcutaneous scars need to reshape the treated area to obtain the best result.

DISCUSSION

The gold standard technique widely approved for body remodeling and skin rejuvenation is lifting.

As it is well-known, it is possible to perform many different kinds of lifting, such as subcutaneous face lift (like the first face lift ever performed in the early twentieth century) deep subcutaneous lift, subcutaneous face lift with suture manipulation of superficial fat and SMAS, subcutaneous face lift with SMASectomy, the Skoog procedure, subperiosteal approach and so on. 1

Thread lift surely represents a less invasive approach compared to the above mentioned techniques and consists in lifting sagging skin using surgical sutures, with small skin incisions. 1, 2, 3 But this is still a surgical approach, with all its side effects and implications such as ecchymosis, erythema, hematoma, swelling, discomfort, and some specific complications like thread exposure which leads to asymmetries(3).

Several studies report the comparison between the different techniques of lifting but in literature still doesn't exist a report about an endo-laser soft lift, using a diode laser, which is comparable in cosmetic outcomes to a standard thread lift (mini lifting) but implies a considerable minor risk and discomfort for the patient. 3, 4, 5, 6, 7, 8, 9, 10, 11 The use of cannula and laser allowed us to take advantage not only of the mechanical action of the cannula used to obtain several tunnels through the subdermal tissues (12), but also of the controlled photothermal injury obtained with laser, that gives skin tightening, retraction and then lifting (13). Diode laser interacts both with water and fat and the most a tissue is rich in water and fat, the better will be laser transmission, with lower dispersion. Moreover fat is particularly rich in glycerol which further facilitates laser effectiveness.

An interesting peculiarity of laser action is the preservation of the interstice, especially concerning vessels; this means less ecchymosis and hematoma.

The most interesting aspect that we have found with Endolaser soft-lift is the induction of a controlled skin retraction, that al-

allows the surgeon to perform, with a safe procedure, a soft endo-lift, with a cosmetic outcomes similar to surgical procedures, but with less trauma and scars. Laser photothermal injury, within the subdermal adipose tissue, induces an increasing in collagen production, thus implying a greater skin elasticity and tightening. The amount of thick septae in the superficial fat layer seems to predict the degree of skin retraction (13).

This procedure should be performed in the same areas that could be treated with a standard thread lift (face and neck, arms, abdomen and legs).

This technique is not indicated for all kind of patients. When a severe skin ptosis is present, the endo-laser soft lift risks to fail patient expectation, not achieving the desired outcomes. The best target is a

medium degree of skin excess.

Using the scanner action, we can also combine endo-laser soft lift and fractional skin rejuvenation; this will give us the best results in skin tightening.

Due to its action on skin remodelling and new collagen fibers production, results are visible three or four months after the last treatment reaching the top in the next six months (14).

CONCLUSIONS

In this preliminary stage of the study we are following up about 20 patients, to be sure the technique is really safe and effectiveness. We believe that many patients treated until now with a standard thread lift technique could have benefits from this new procedure of endo-laser soft lift, achieving

FIGURE 1. Pre-operative view

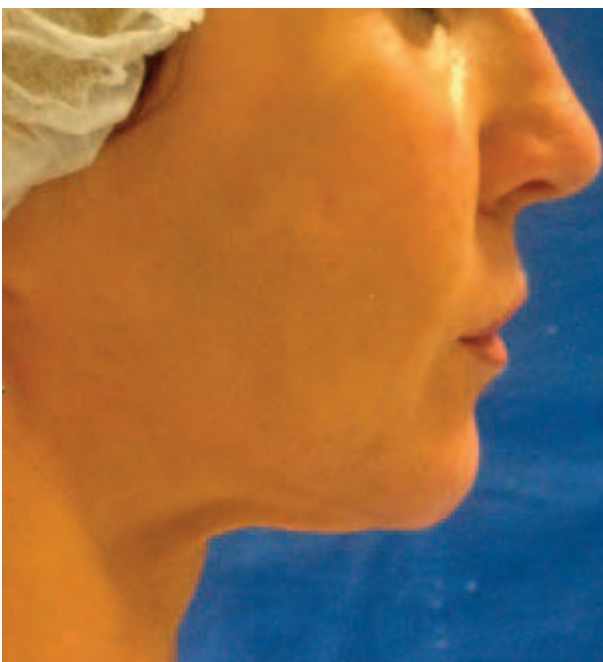
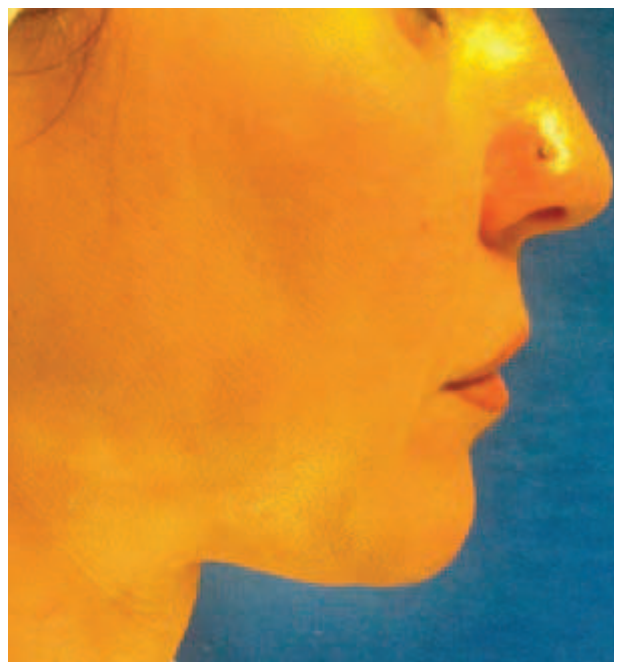
FIGURE 2. 4 months after 1 pass of endlift



stackable cosmetic outcomes with minor discomfort, pain and scarring. However more studies must be done.

REFERENCES

1. Face Lift Richard J. Warren, F.R.C.S.C. Sherrell J. Aston, F.A.C.S. Bryan C. Mendelson, F.R.C.S.E., F.R.A.C.S., F.A.C.S.; *Plast. Reconstr. Surg.* 128: 747e, 2011
2. Stensen Duct Rupture (Sialocele) and Other Complications of the Aptos Thread Technique Eyal Winkler, Oren Goldan, Eli Regev, David Mendes, Arie Orenstein, Josef Haik *Plast. Reconstr. Surg.* 118: 1468, 2006
3. Face Lift Richard J. Warren, F.R.C.S.C. Sherrell J. Aston, F.A.C.S. Bryan C. Mendelson, F.R.C.S.E., F.R.A.C.S., F.A.C.S.; *Plast. Reconstr. Surg.* 128: 747e, 2011.
4. Secondary Rhytidectomy: Comprehensive Review and Current Concepts Yvonne M. Rasko, M.D. Evan Beale, M.D. Rod J. Rohrich, M.D. *Plast. Reconstr. Surg.* 130: 1370, 2012
5. Composite rhytidectomy Hamra *Plast. Reconstr. Surg.* July 1992
6. Owsley JQ Jr. Platysma-fascial rhytidectomy: A preliminary report. *Plast Reconstr Surg.* 1977;60:843–850
7. Aston SJ. Platysma-SMAS cervicofacial rhytidoplasty. *Clin Plast Surg.* 1983;10:507–520 Marten TJ.
8. High SMAS facelift: Combined single flap lifting of the jawline, cheek, and midface. *Clin Plast Surg.* 2008;35: 569–603.